




Acute Leukemia Immunophenotyping

Brent Wood MD, PhD

Department of Pathology and Laboratory Medicine
Childrens Hospital Los Angeles

Acute Leukemia

- **Diagnosis** 
 - 20% blasts by morphology
- **Classification**
 - **Lineage assignment** 
 - Acute myeloid leukemia (AML)
 - B lymphoblastic leukemia (B-ALL or B-LL)
 - T lymphoblastic leukemia (T-ALL or T-LL)
 - Mixed phenotype acute leukemia (MPAL)
 - Cytogenetic/Molecular lesions
- **Prognostication**
 - Age, white count
 - Cytogenetic/Molecular lesions
- **Post-therapeutic Monitoring** 

Blast Enumeration

- Blast estimates by flow cytometry may not agree with morphology

- Blast % (morphology) = # blasts / # nucleated cells * 100

1. Blasts defined differently by morphology and flow cytometry

- Include promonocytes, promyelocytes, immature B cells as appropriate


2. Specimen handling and processing



- Red blood cell lysing reagents

- Erythrocyte progenitors lose FS

- Erythroids under-represented if threshold is high



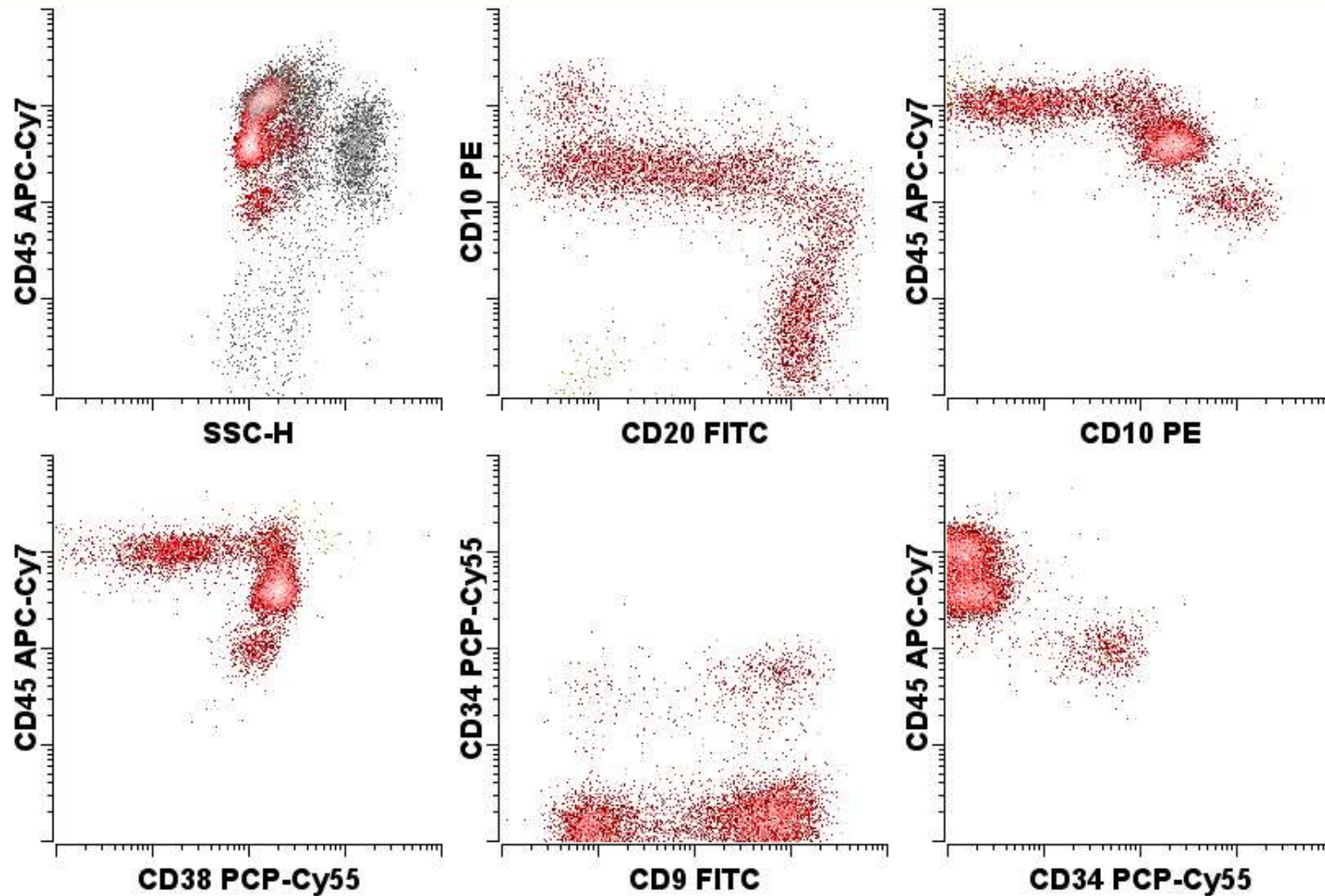
- Variable degree of peripheral blood dilution

- All marrow aspirates have hemodilution

- No simple way to correct

- Blast estimate may be high or low depending on relative contributions

Acute Leukemia ?

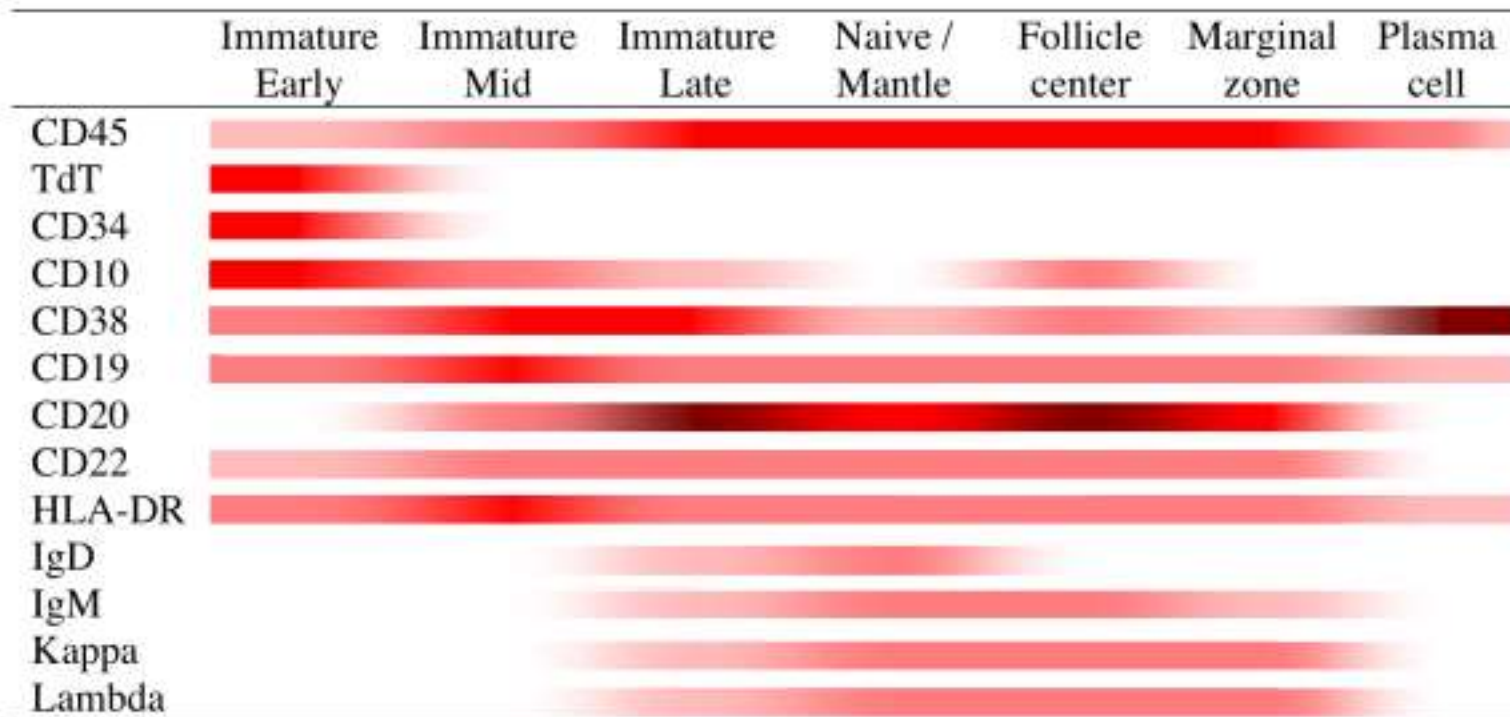


37% blasts morphology, 34% progenitors flow cytometry

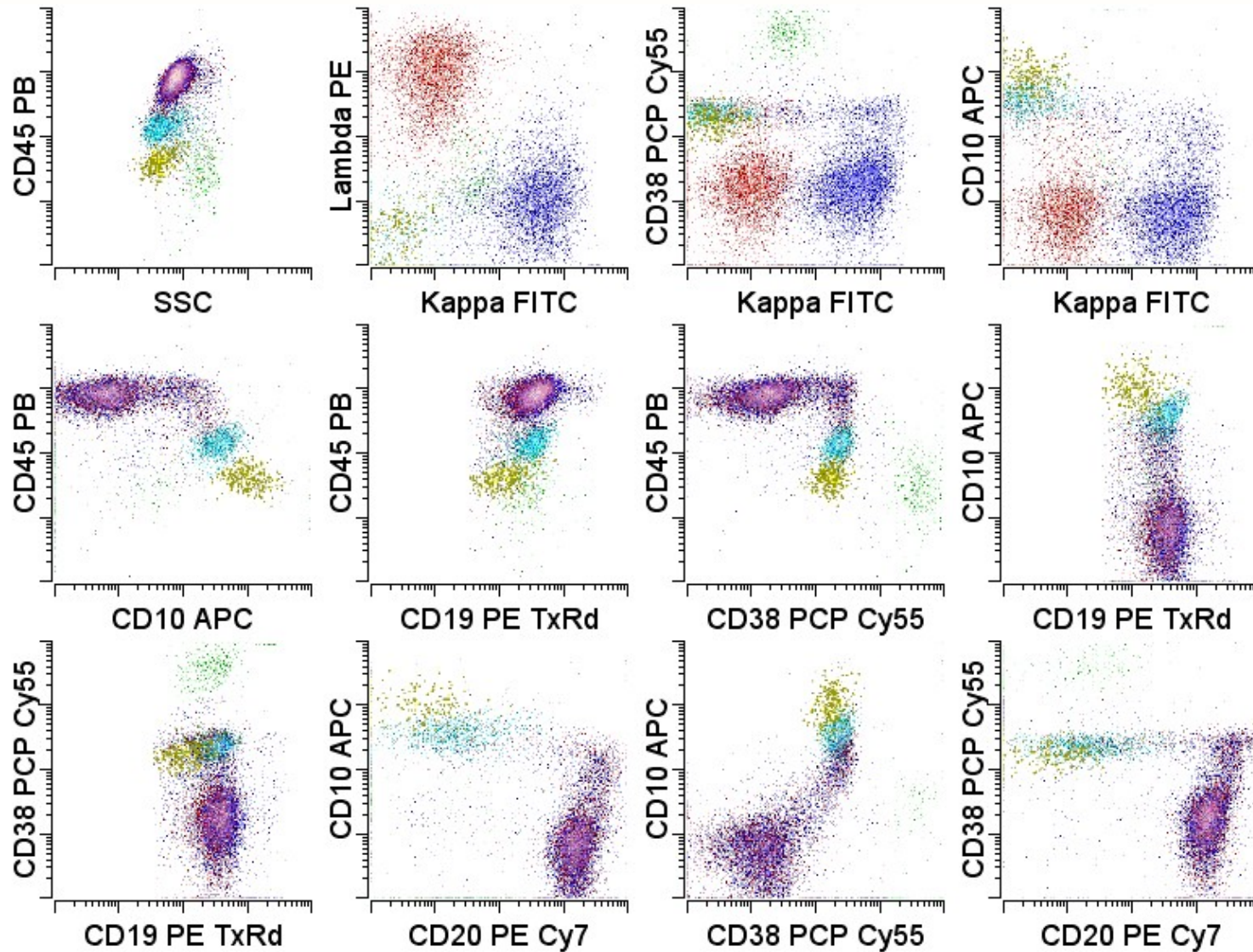
Abnormal population identification

- Normal
 - Antigens expressed in consistent and reproducible patterns with maturation
- Neoplastic
 - Increased or decreased normal antigens
 - Asynchronous maturational expression
 - Aberrant antigen expression
 - Homogeneous expression

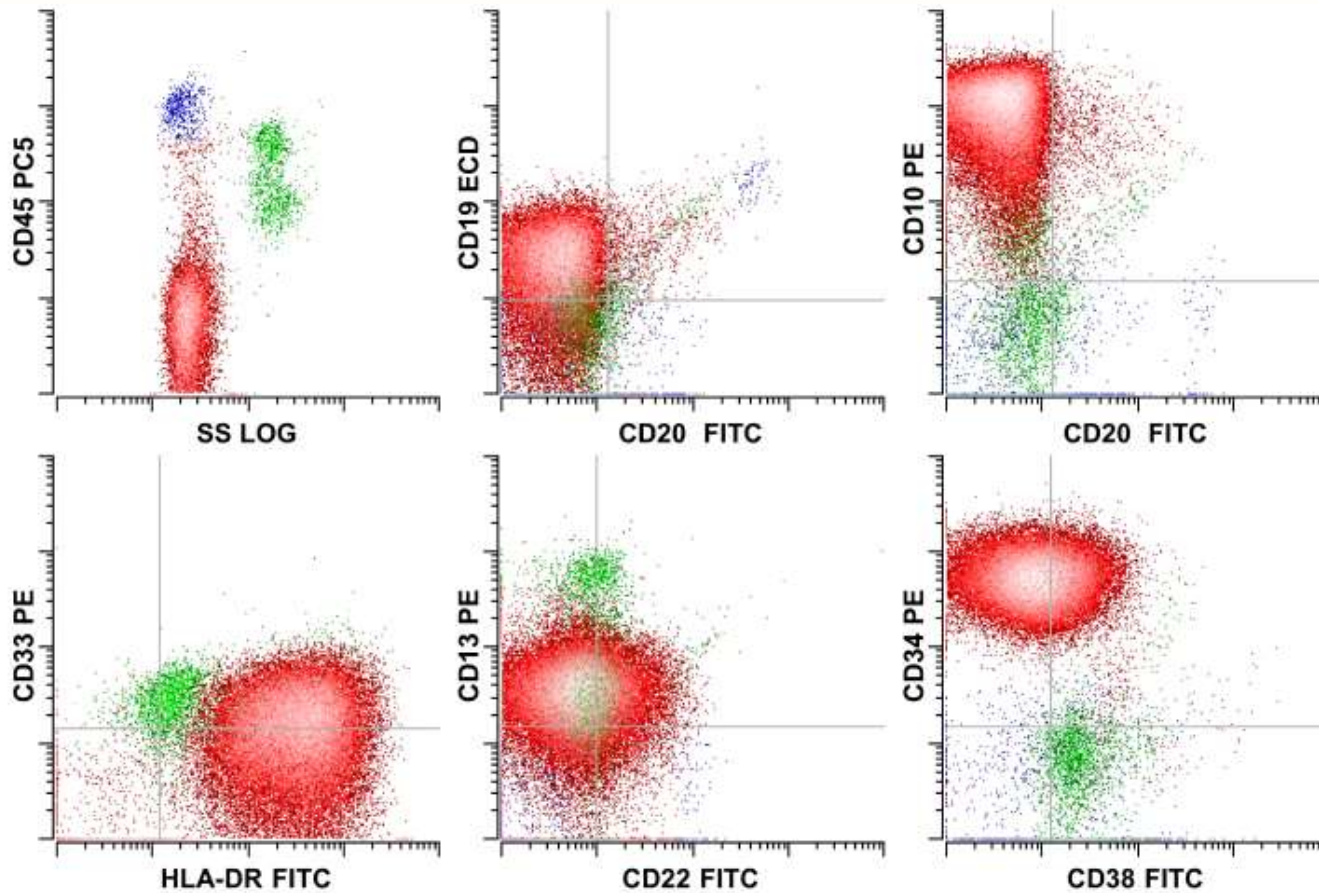
Normal B cell Maturation



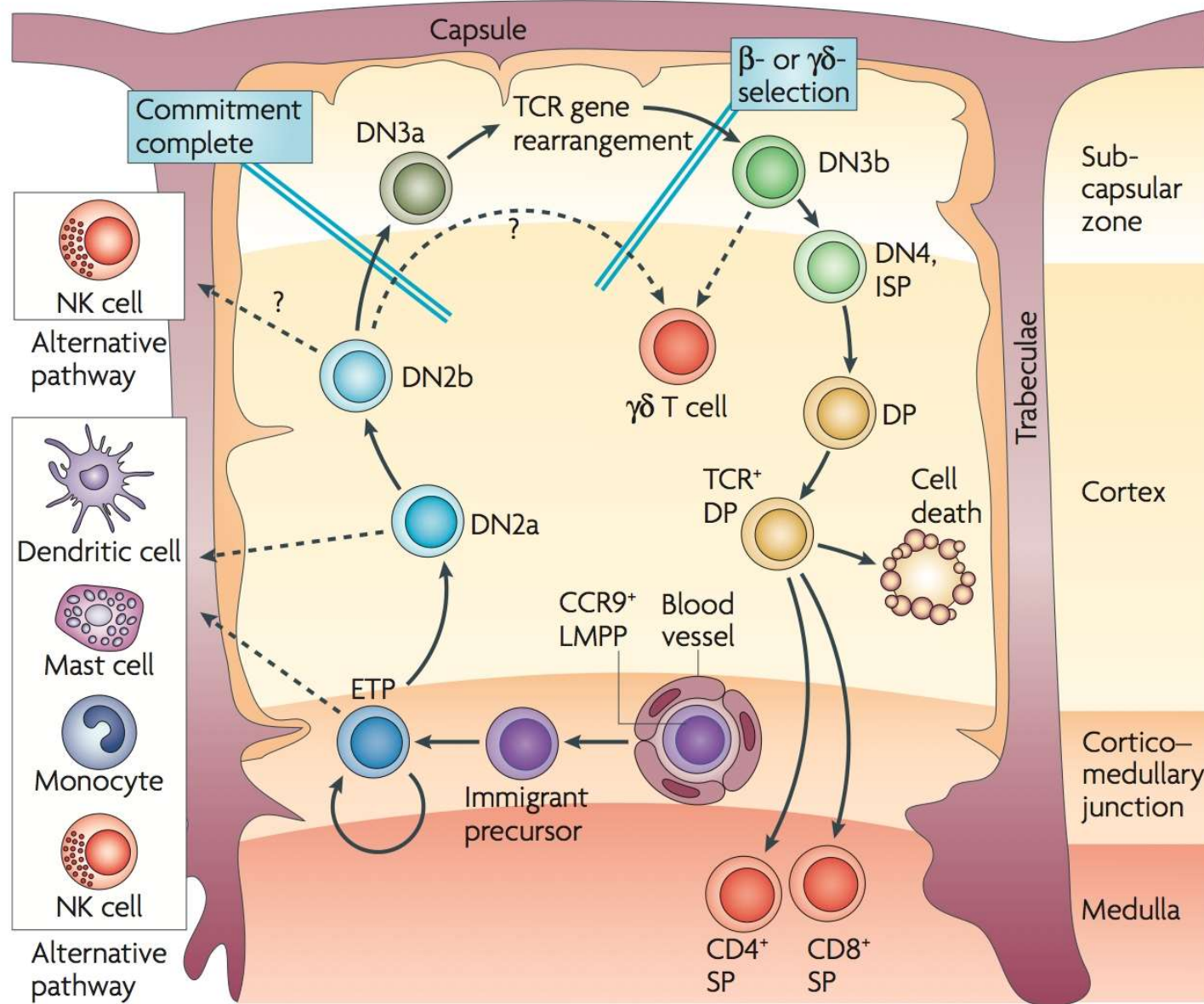
Normal B cell Maturation



Precursor B cell Lymphoblastic Leukemia



Wood and Borowitz (2006) Henry's Laboratory Medicine



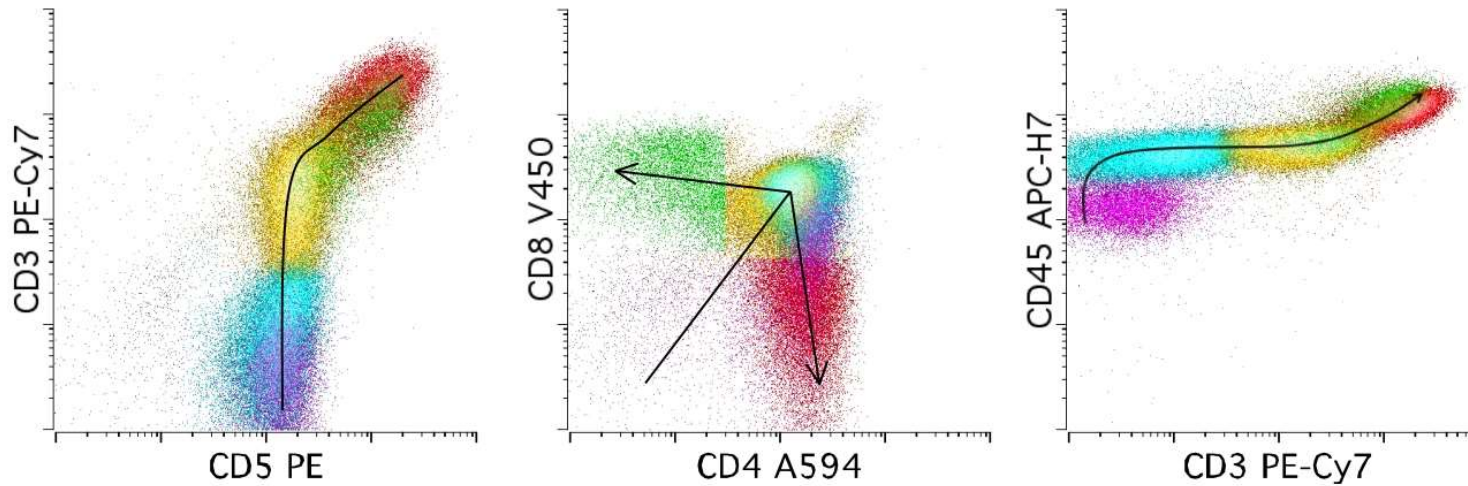
Rothenberg, et al (2008) Nat Reviews 8:9-21

Normal T cell Maturation

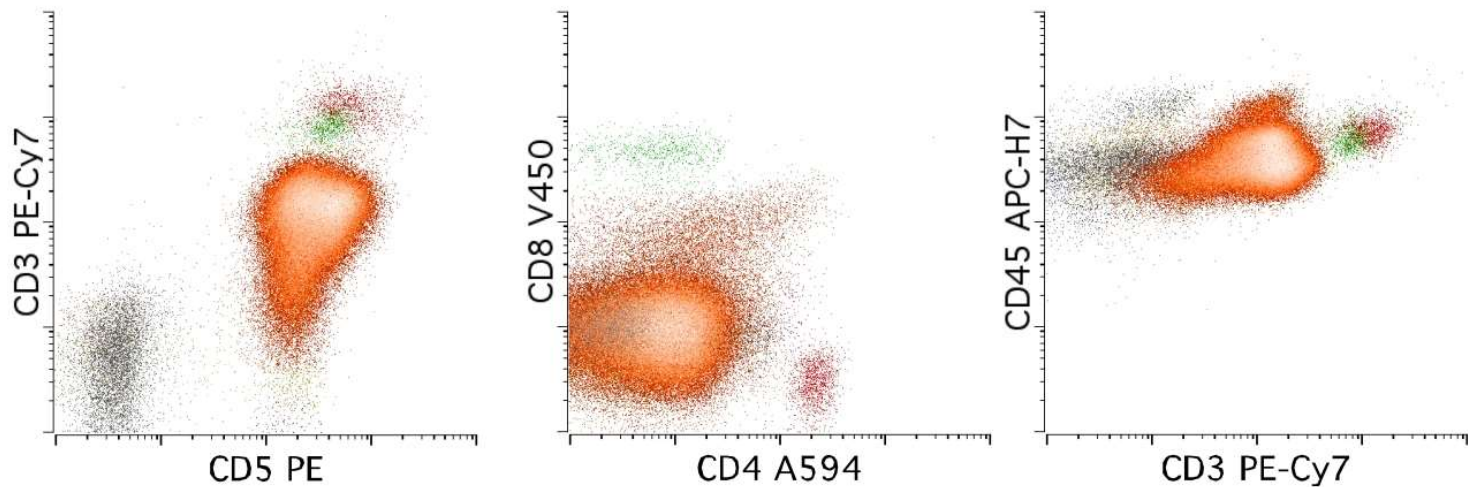
	Prothymocyte	Immature Thymocyte	Common Thymocyte	Mature Thymocyte	Mature T-cell
CD45	Strong	Strong	Strong	Strong	Strong
CD34	Strong	Weak	None	None	None
TdT	Strong	Strong	Strong	Weak	None
CD7	Strong	Strong	Strong	Strong	Strong
CD2	Strong	Strong	Strong	Strong	Strong
CD5	Strong	Strong	Strong	Strong	Strong
cCD3	Weak	Strong	Strong	Strong	Strong
CD4	None	Strong	Strong	Strong	Strong
CD8	None	Strong	Strong	Strong	Strong
CD3	None	None	Strong	Strong	Strong
TCR	None	None	Strong	Strong	Strong

Precursor T-cell Lymphoblastic Leukemia

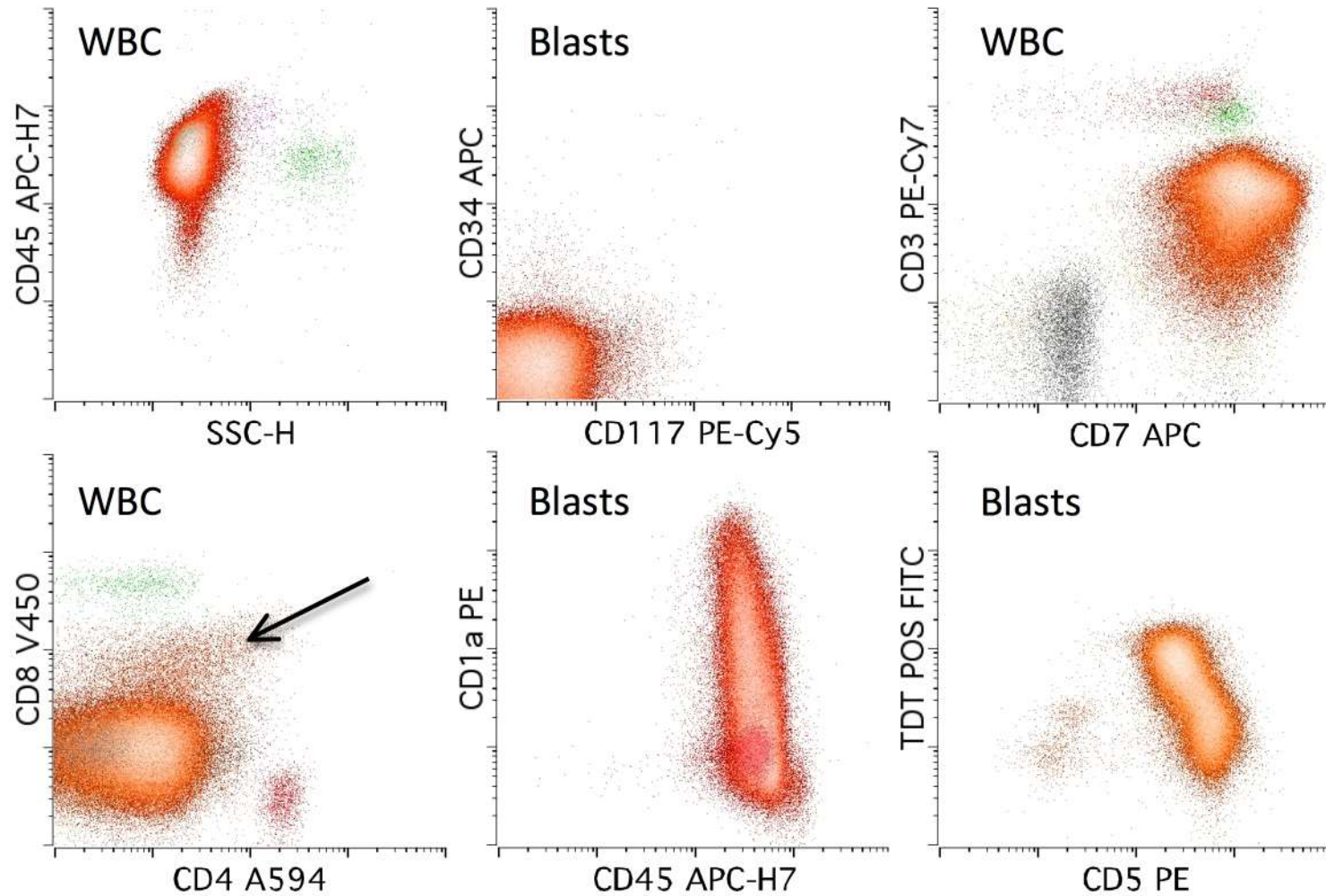
A) Thymic tissue



B) T-ALL



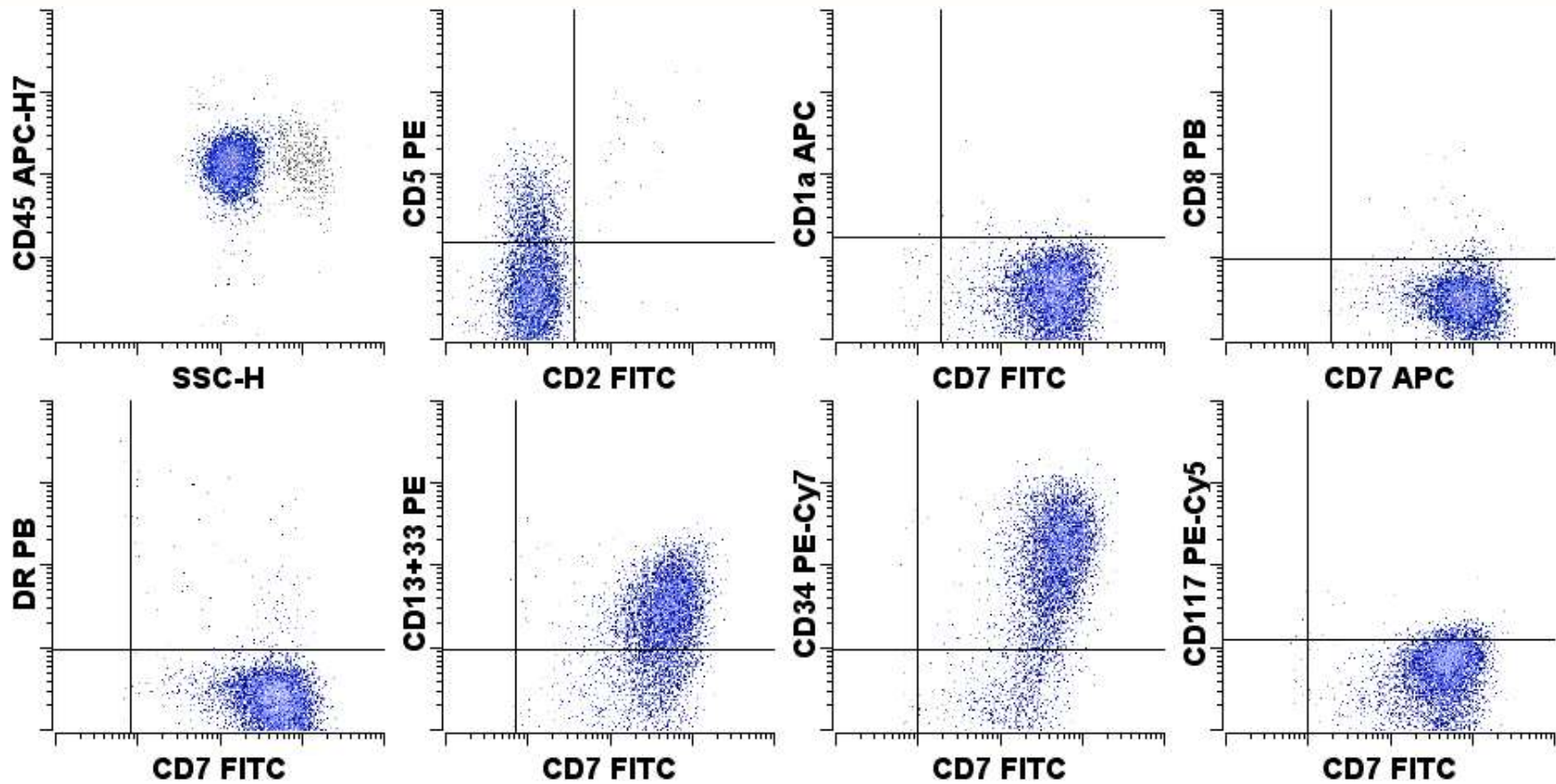
Precursor T-cell Lymphoblastic Leukemia



Early Thymic Precursor T-ALL

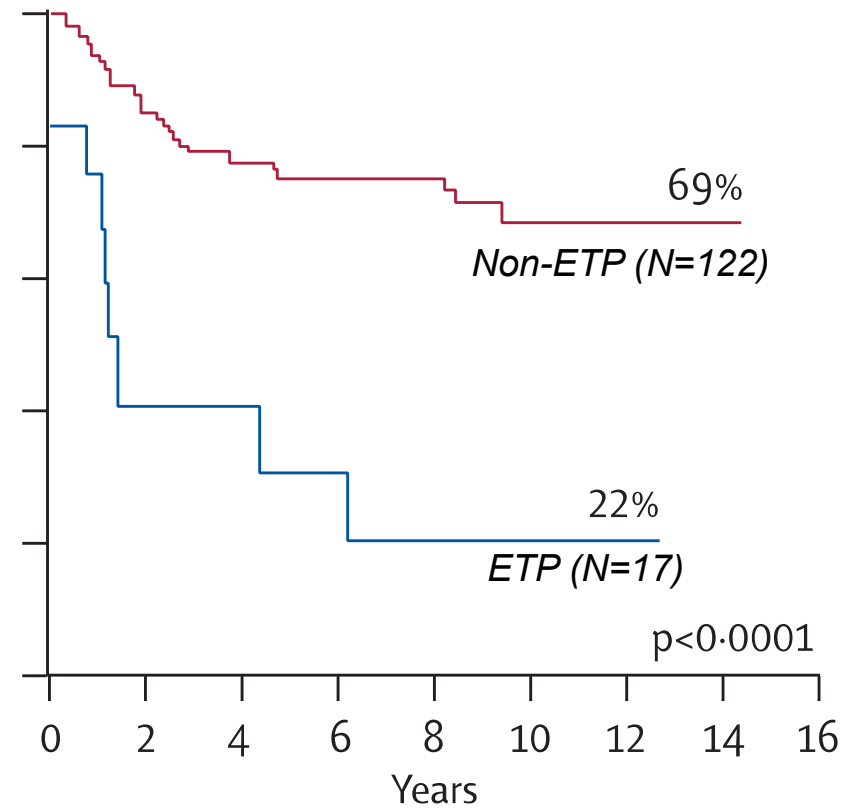
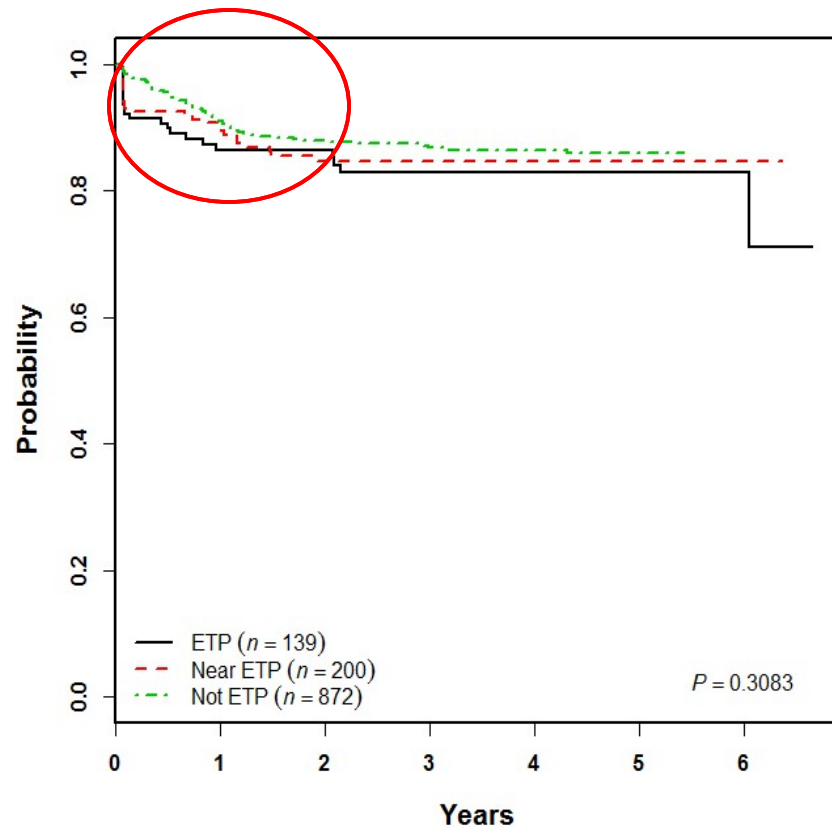
- CD1a and CD8 negative
- **CD5 < 75% positive**
- HLA-DR, CD13, CD33, CD34 or CD117 positive
- Overlap with MPAL
 - Dependent on cyto CD3
 - Absence of MPO or monocytic antigens

ETP T-ALL Pretreatment



AALL0434 - Event-Free Survival

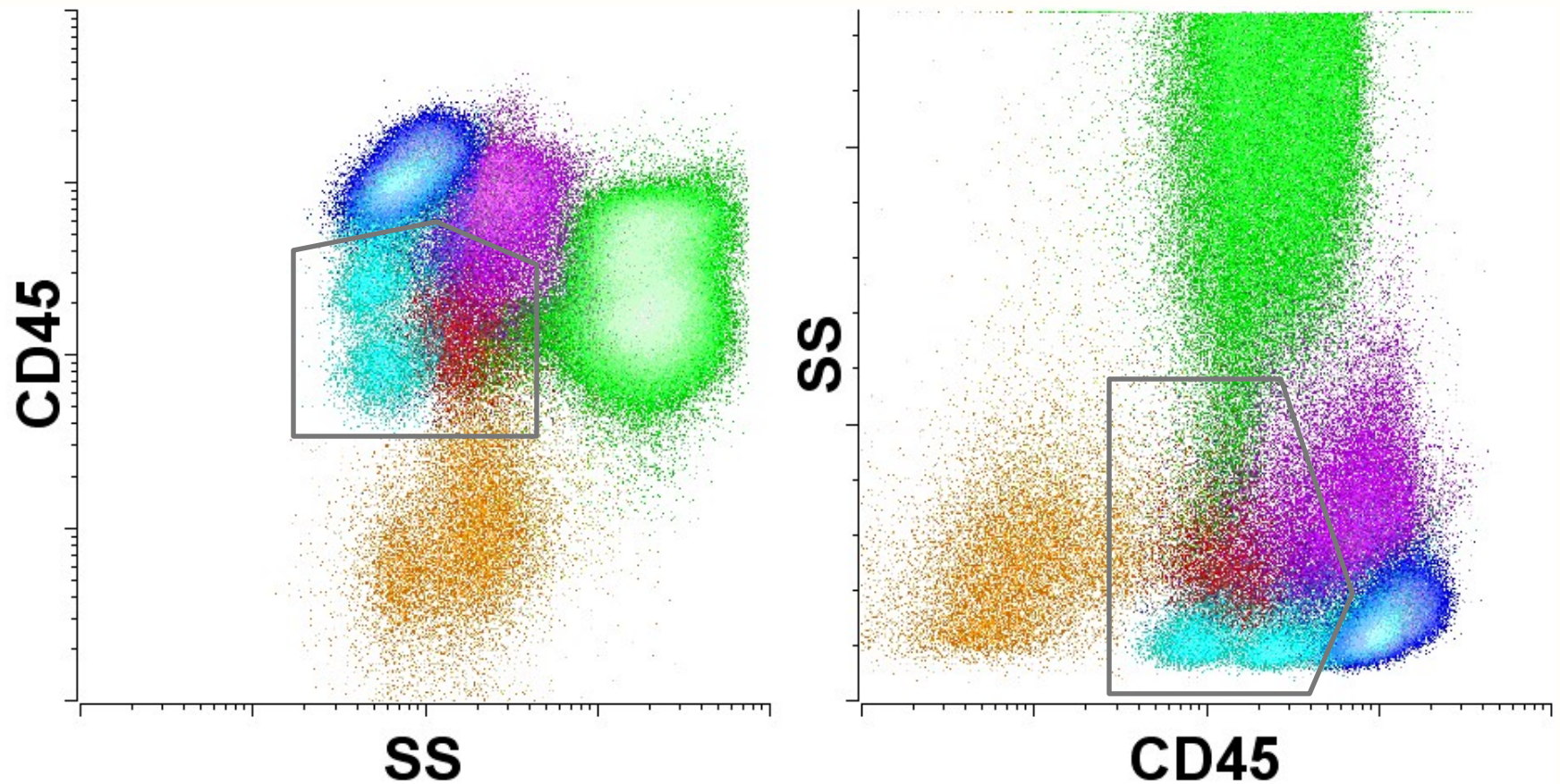
Event Free Survival



Coustan-Smith et al, Lancet Oncology 2009; 10:147-56

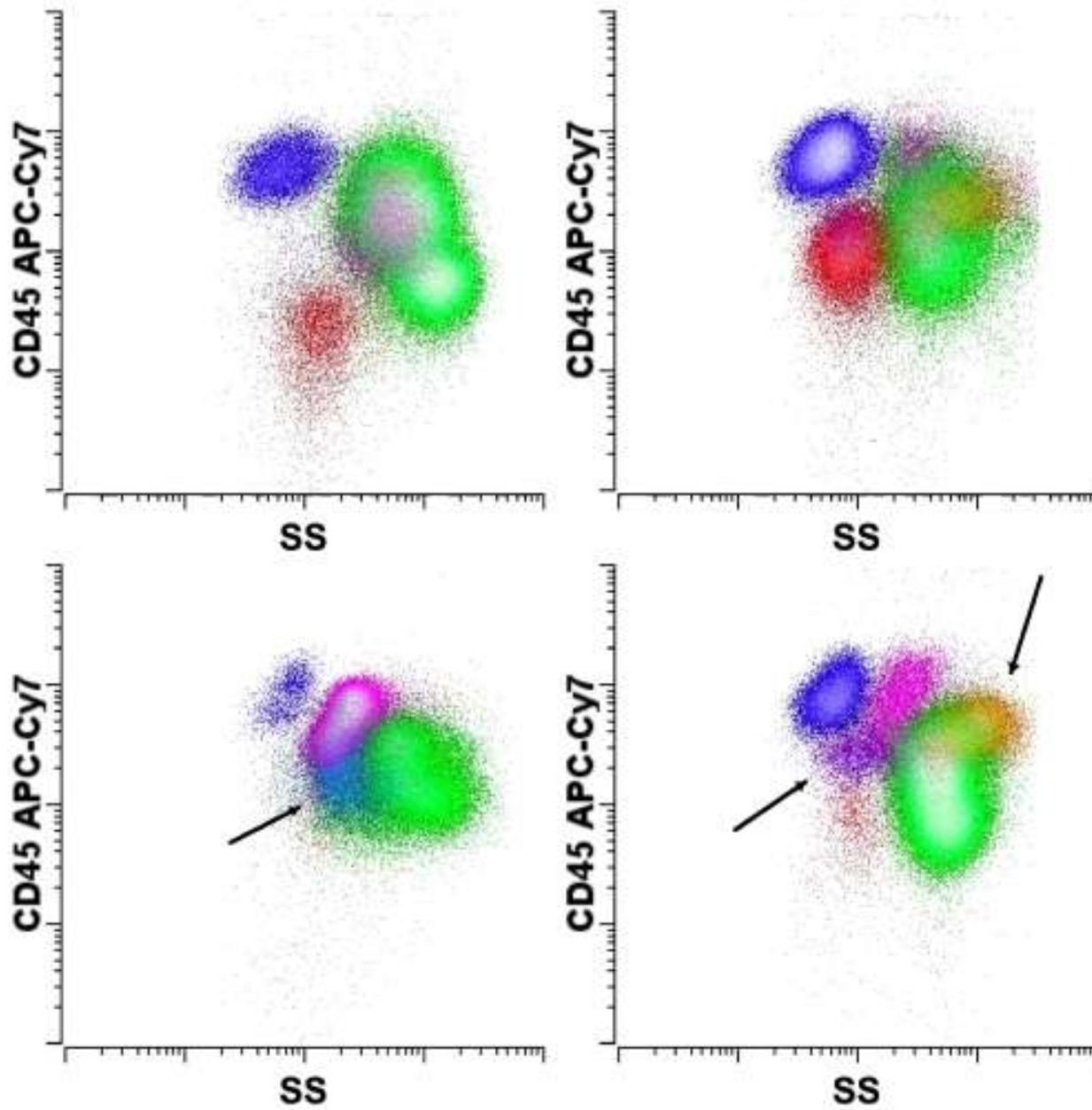
Intent to Treat analysis

Cell Type Identification



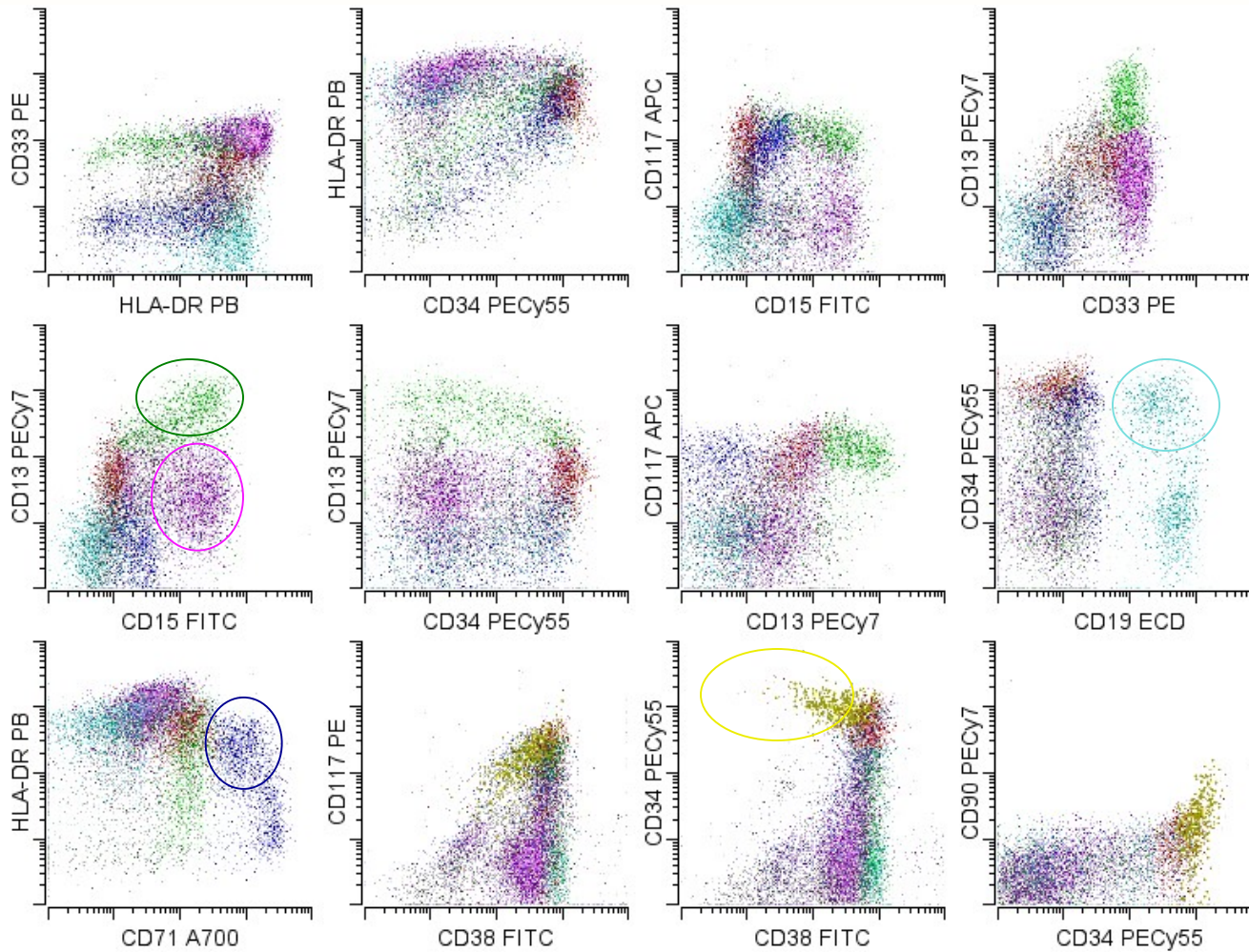
Borowitz et al (1993) AJCP 100:534-40.

Steltzer et al (1993) Ann NY Acad Sci 667:265-280

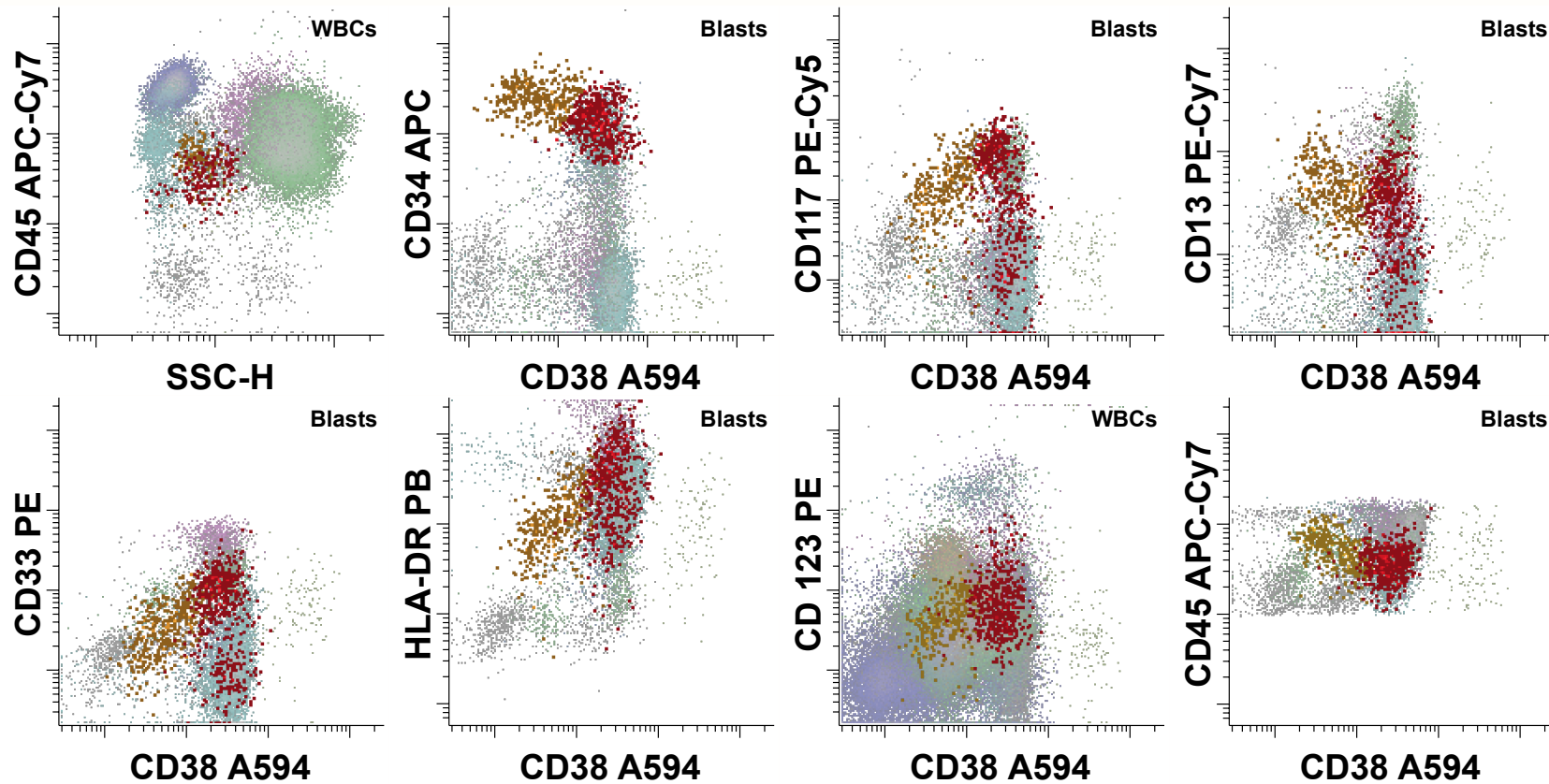


Wood (2007) *Clinics in Lab Medicine* 27:551-575

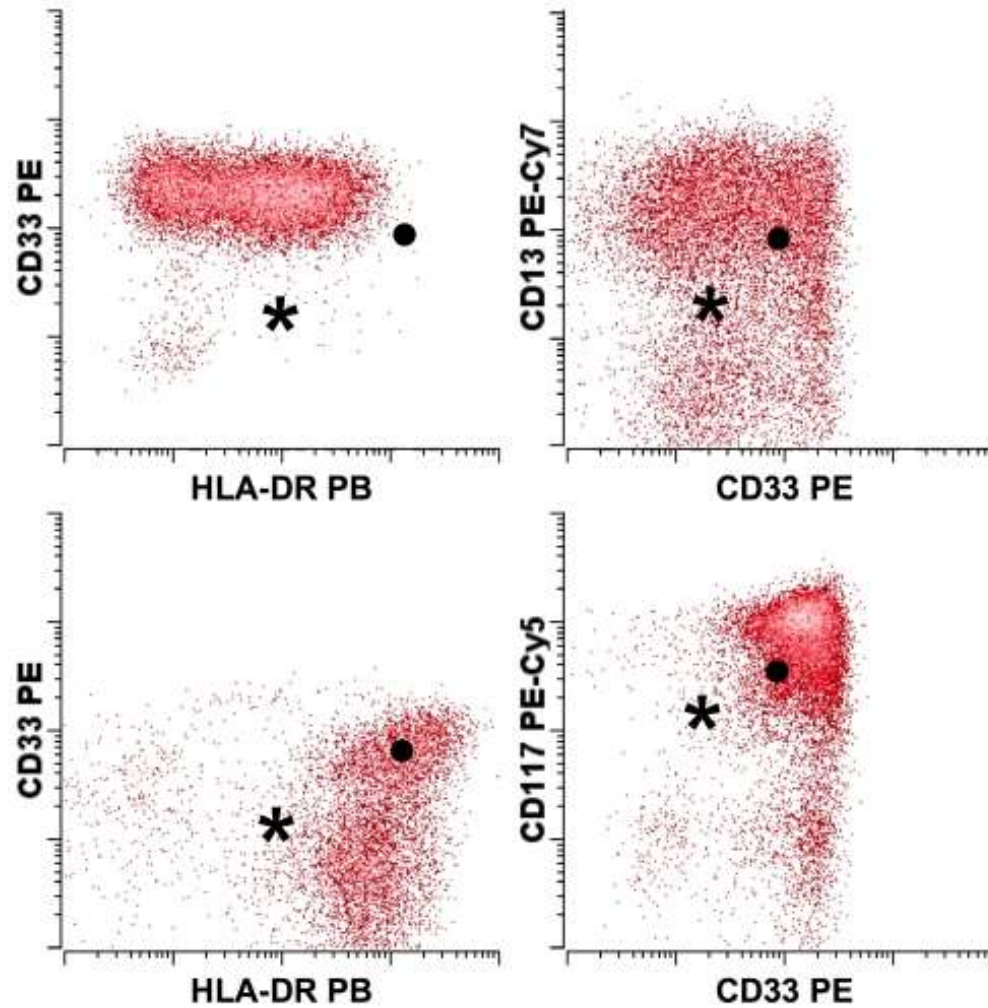
Normal Blast Maturation



Normal CD34+ Progenitors

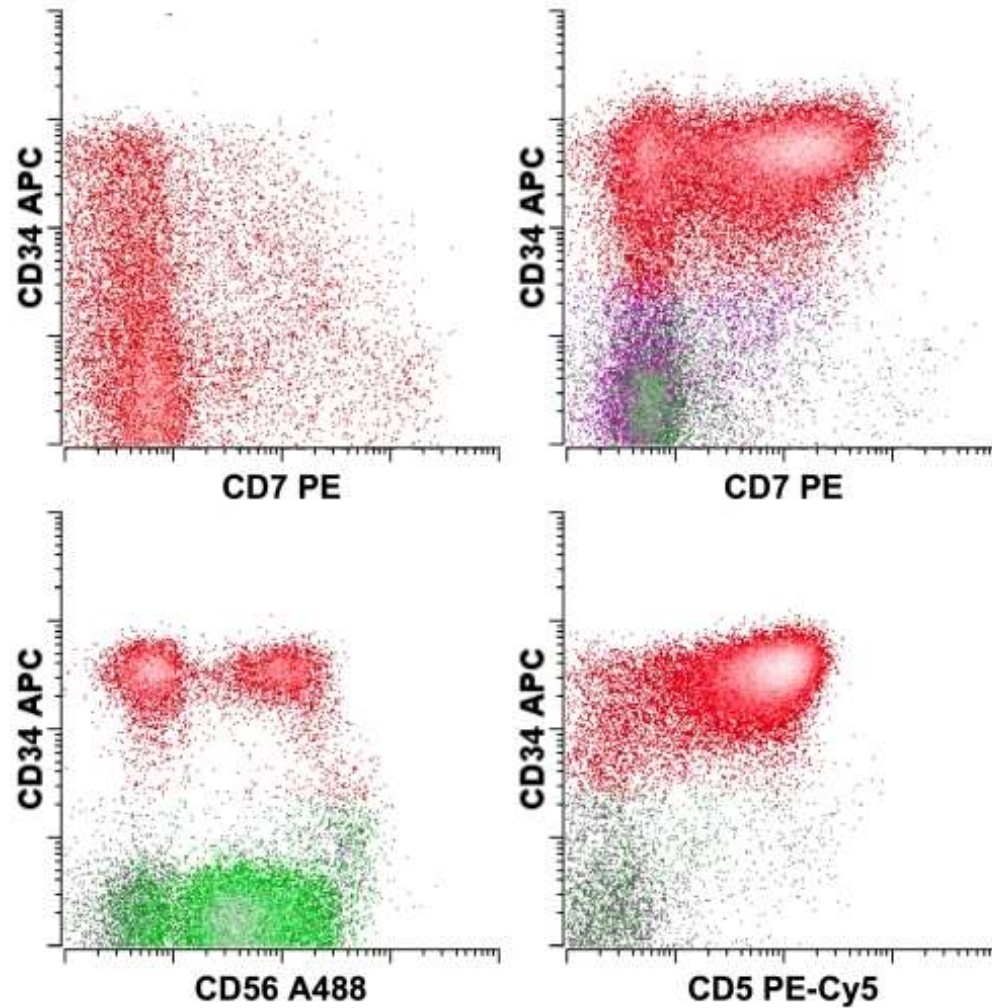


Blasts - Abnormal Antigen Intensity



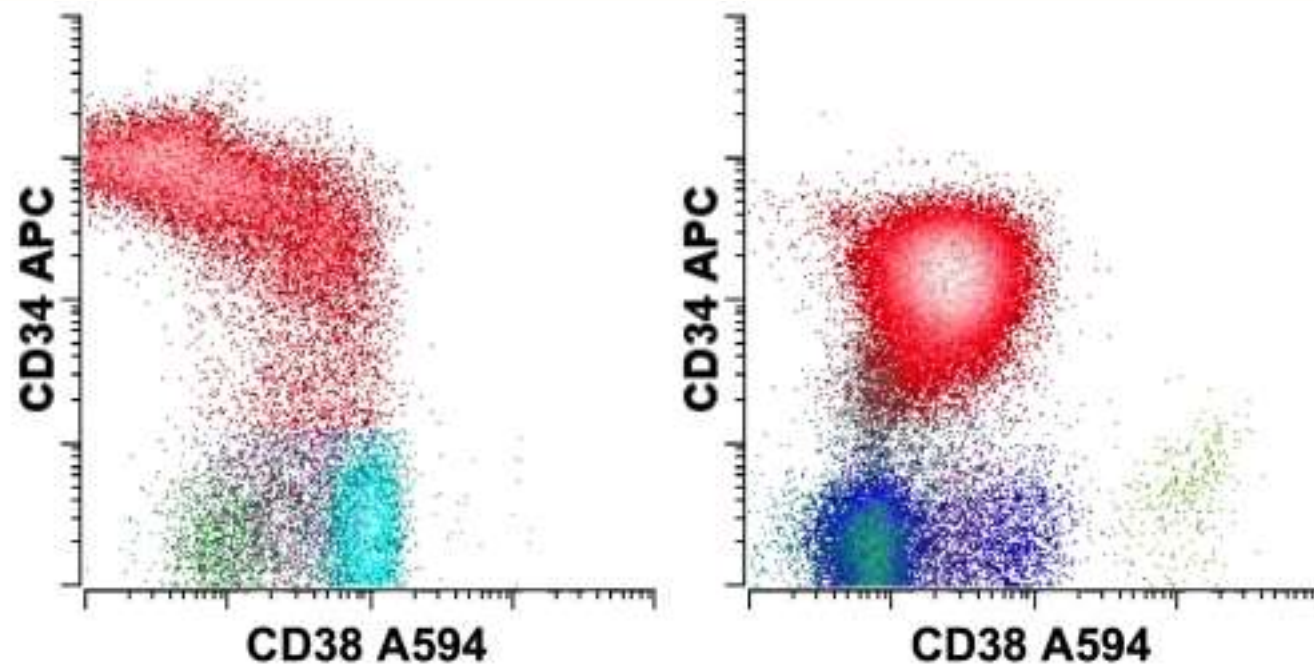
Wood (2007) Clinics in Lab Medicine 27:551-575

Blasts - Aberrant Lymphoid Antigens



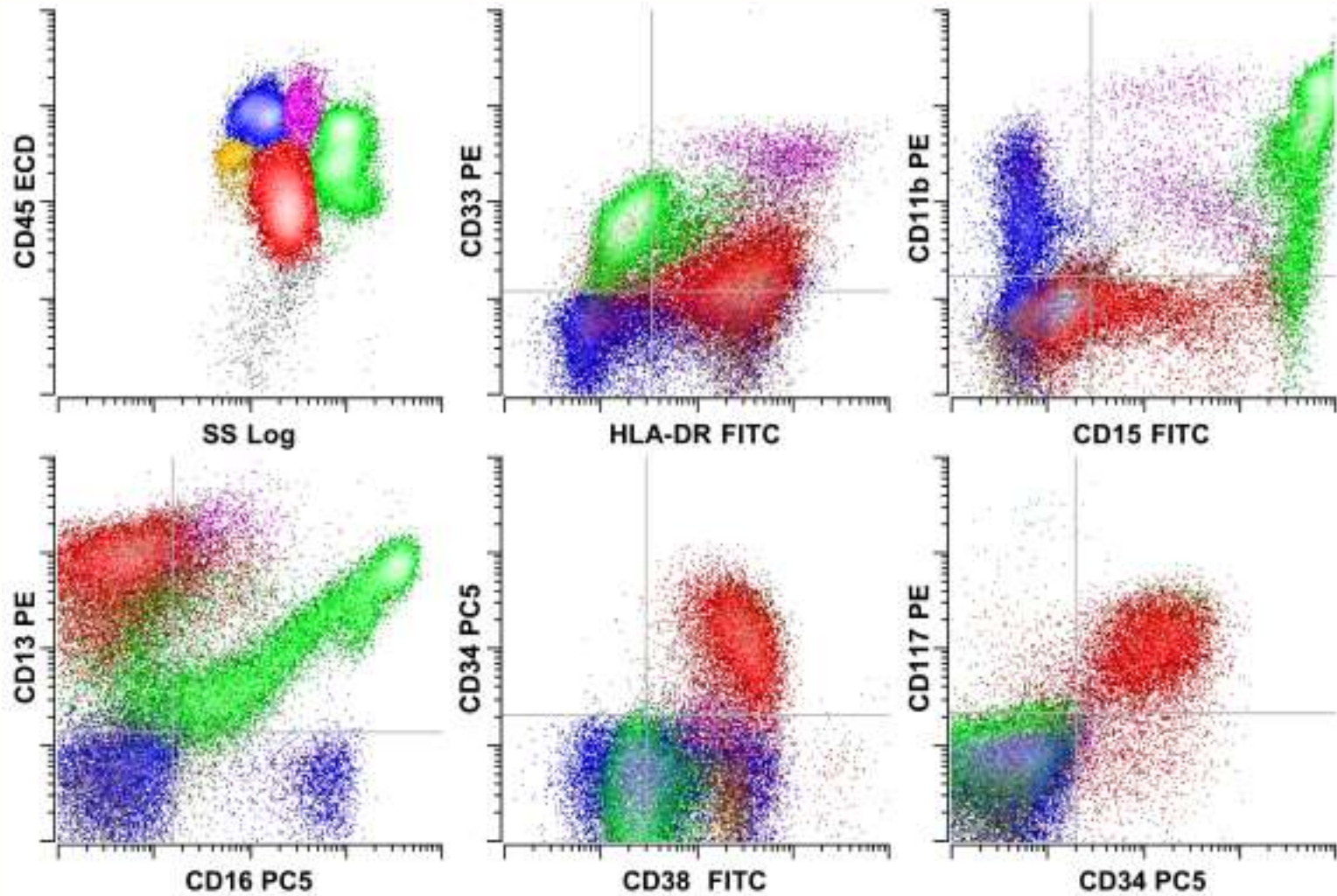
Wood (2007) Clinics in Lab Medicine 27:551-575

Blasts - Aberrant Maturation



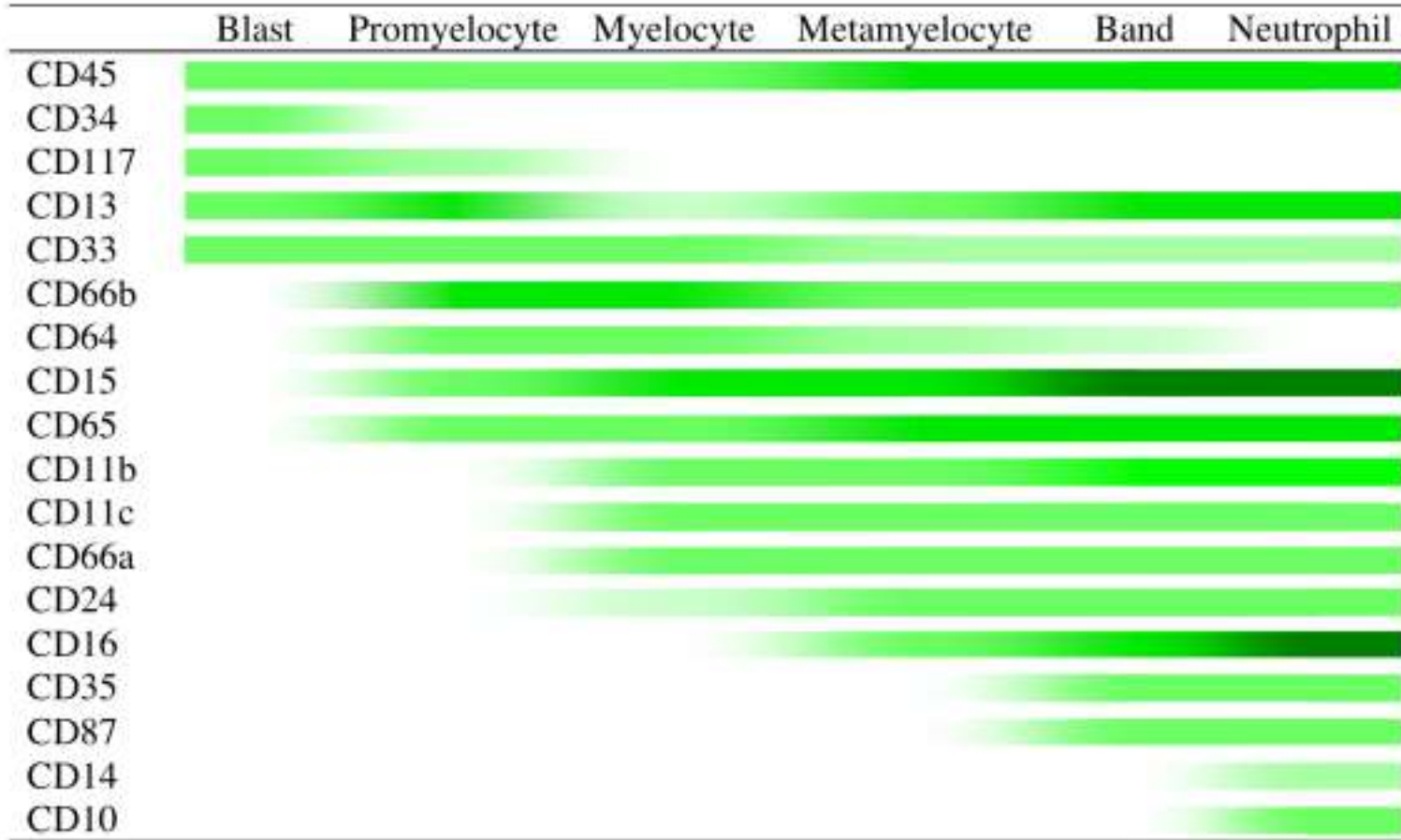
Wood (2007) Clinics in Lab Medicine 27:551-575

Acute Myeloid Leukemia

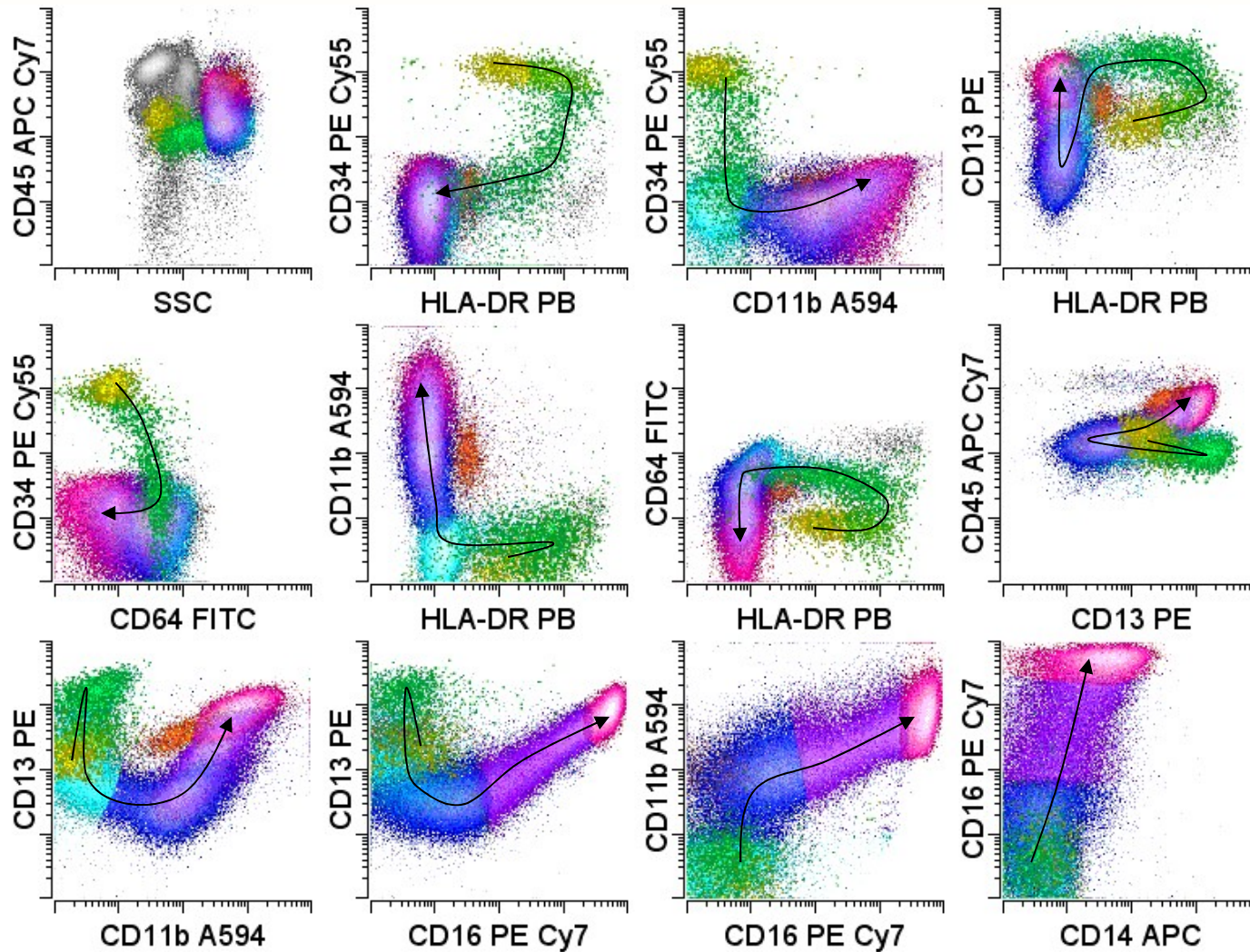


Wood and Borowitz (2006) Henry's Laboratory Medicine

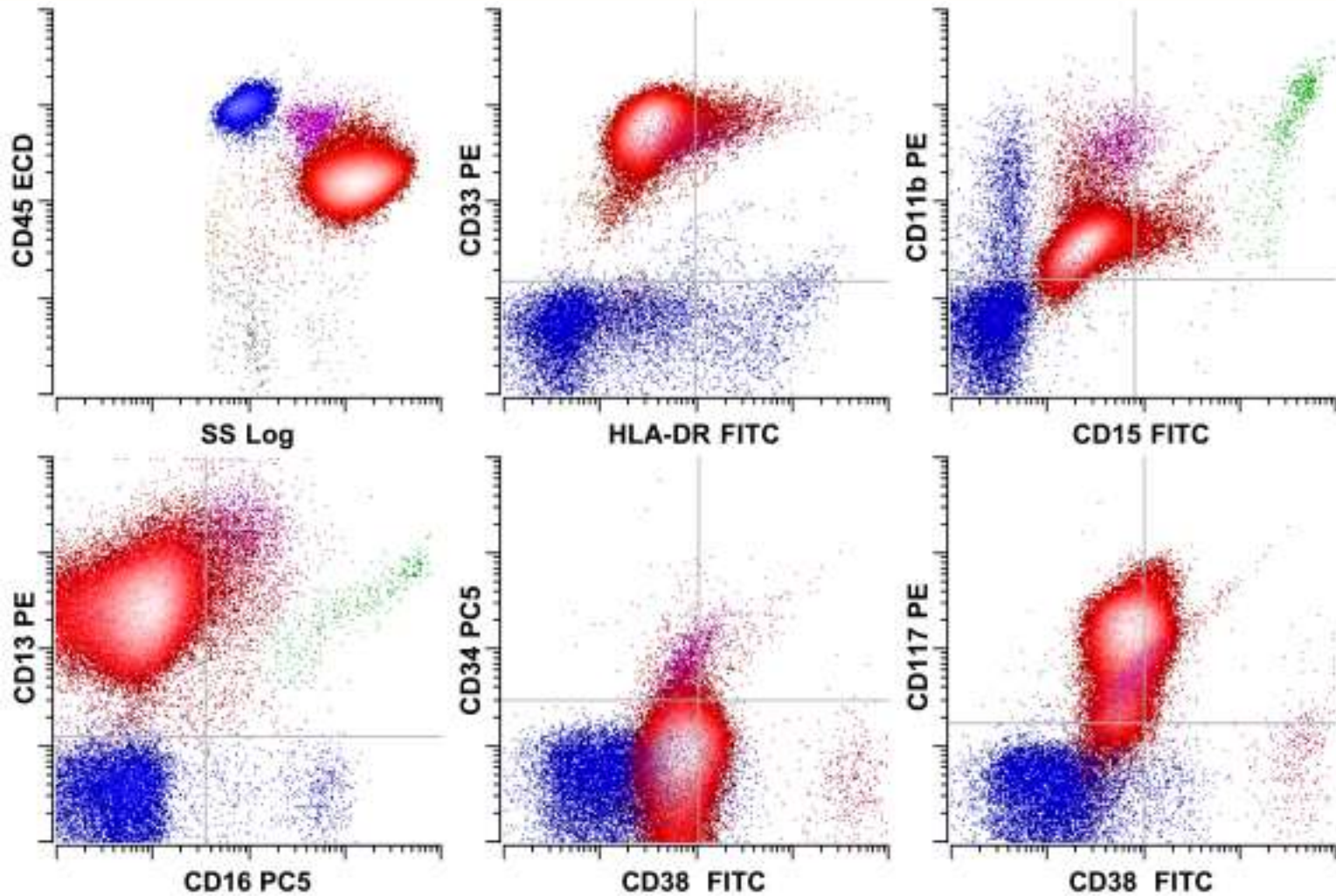
Normal Granulocytic Maturation



Normal Granulocytic Maturation




Acute Promyelocytic Leukemia

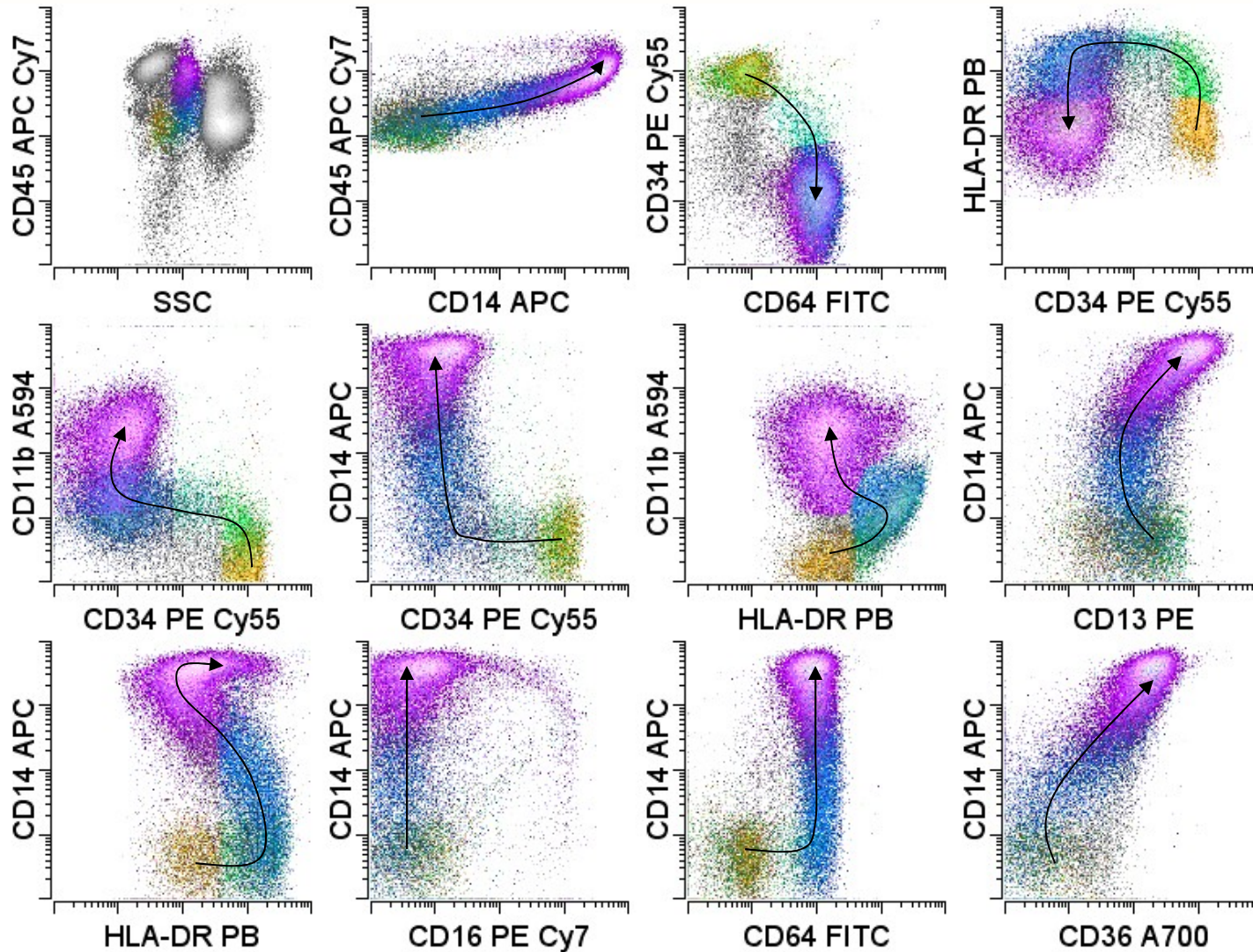


Wood and Borowitz (2006) Henry's Laboratory Medicine

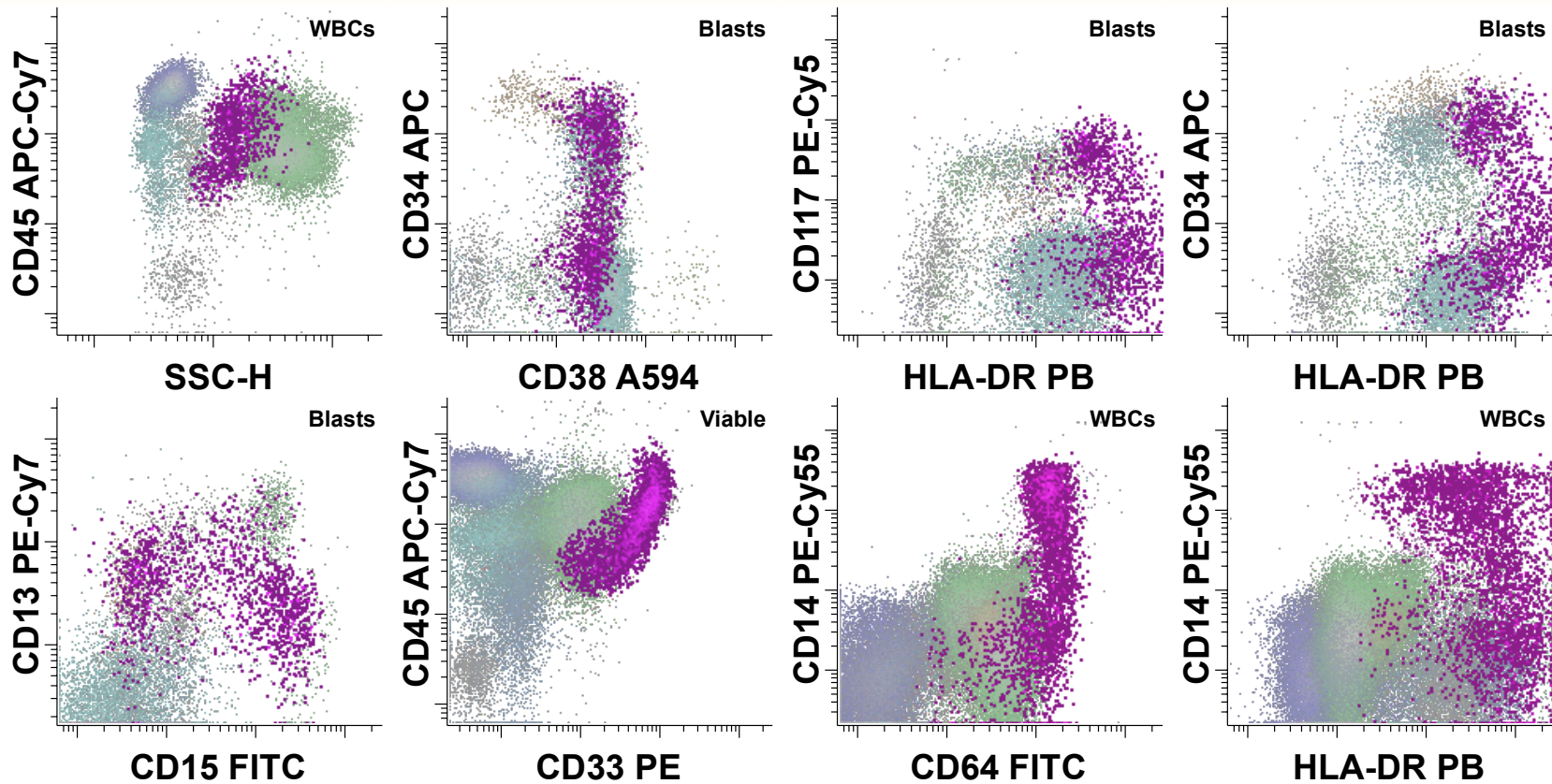
Normal Monocytic Maturation



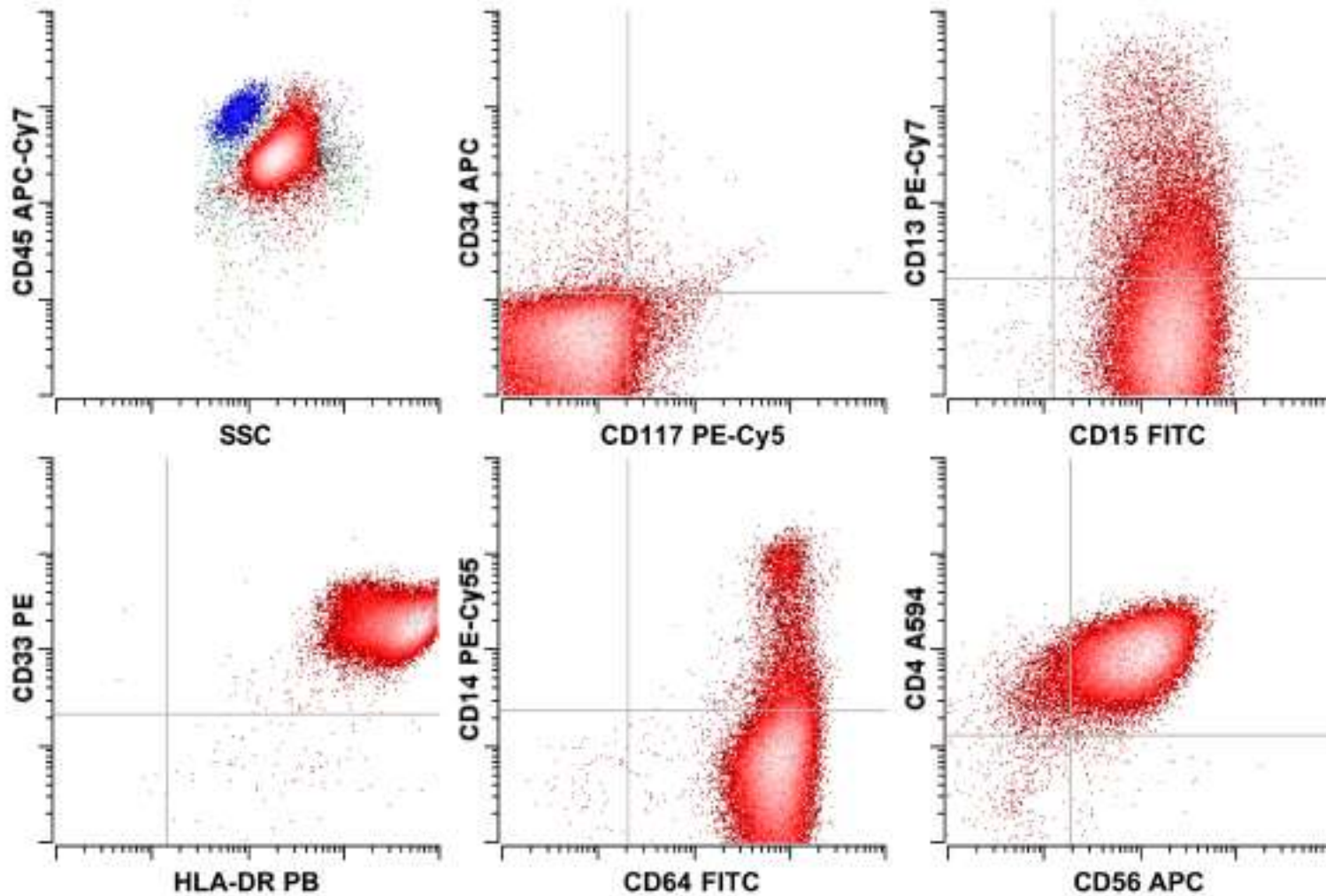
Normal Monocytic Maturation



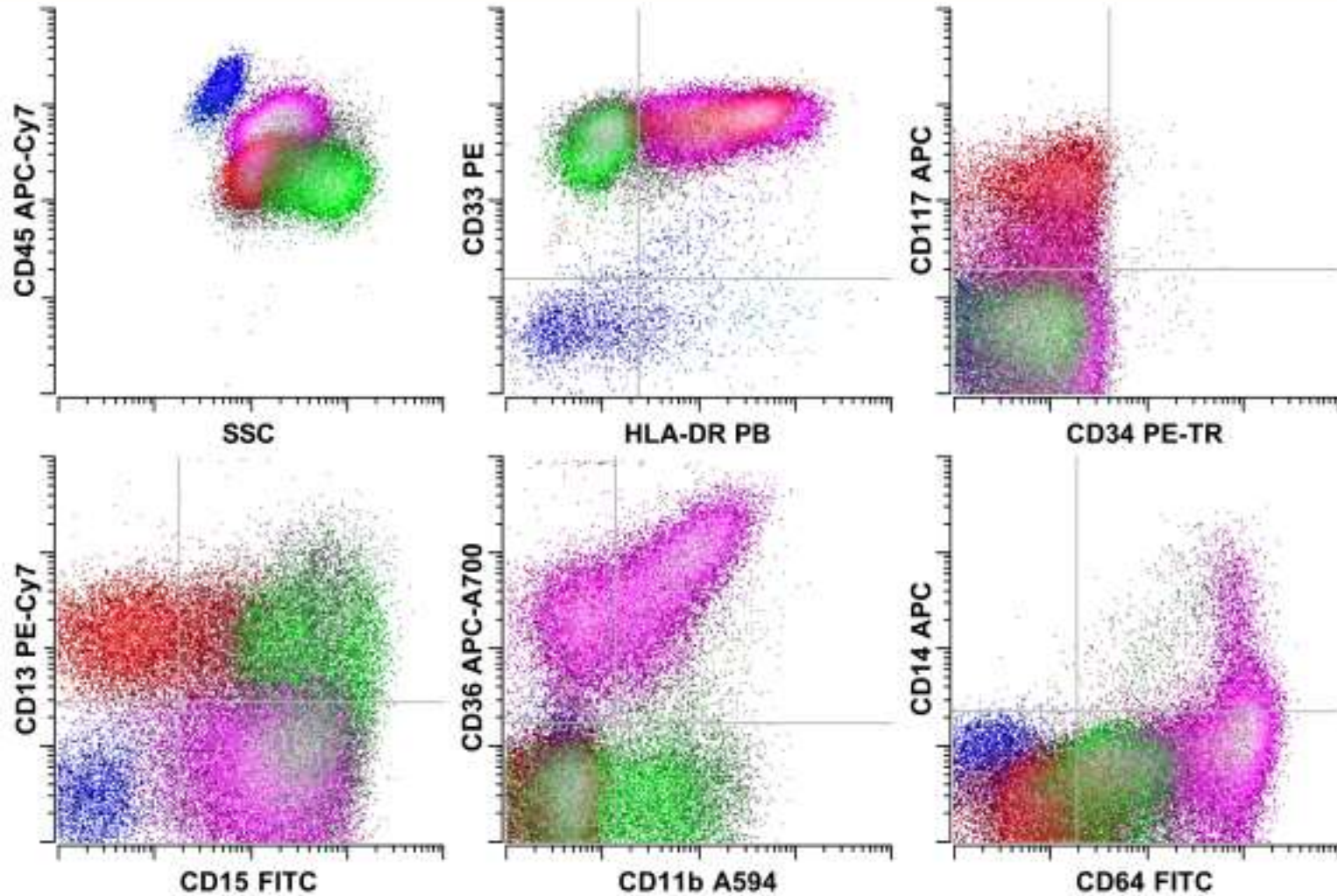
Monocytic Maturation



Acute Monocytic Leukemia



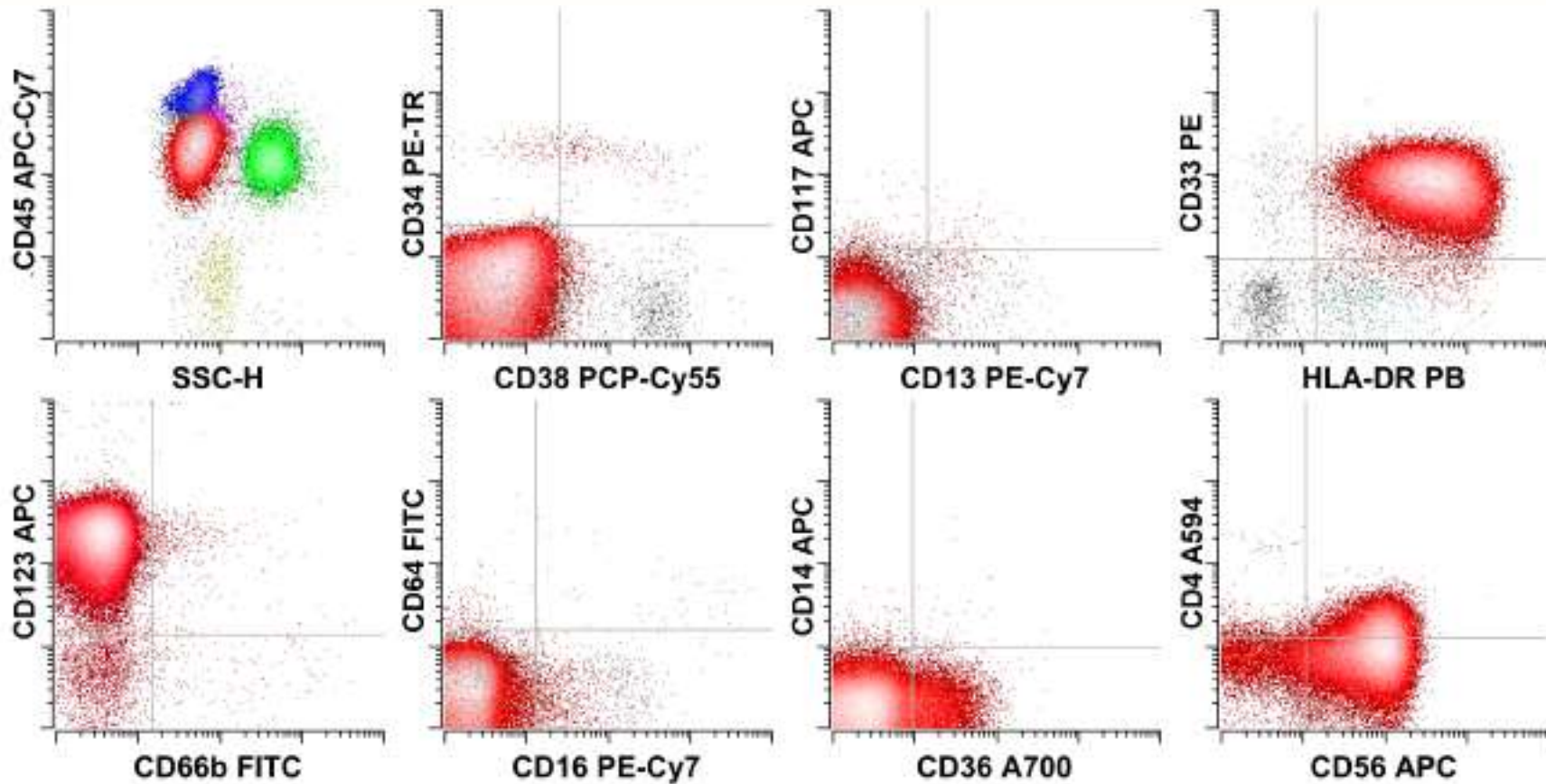
Acute Myelomonocytic Leukemia



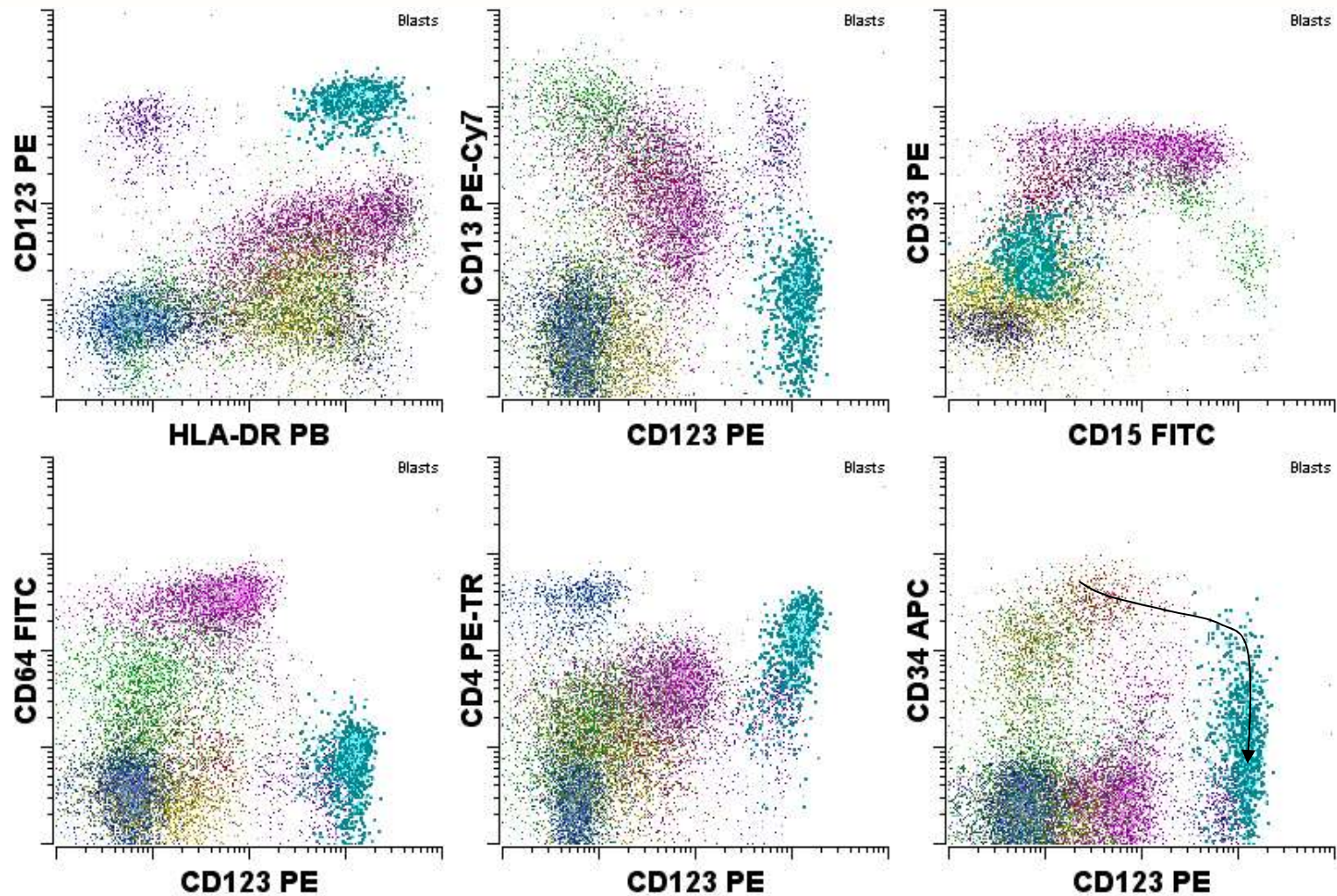
Wood and Borowitz (2006) Henry's Laboratory Medicine

Dendritic Cell Leukemia

“Blastic NK cell lymphoma”



Plasmacytoid Dendritic Cells



Lineage Assignment

- Composite immunophenotype is used for lineage assignment
 - Do not rely on single antigen expression
 - B cell - CD19, CD20, Ig, bright CD10, cCD22 or cCD79a
 - T cell - sCD3 or cCD3
 - Myeloid - cMPO, CD13, CD33, CD117 or monocytic (CD64, CD14)
- The closer the expression level of an antigen is to that seen on normal populations, the more likely it reflects lineage
- Maturation stage assigned in relation to the closest corresponding normal stage of maturation
 - Immature antigens - CD34, CD117, nTdT

Classification of Mixed Phenotype Acute Leukemia (MPAL)

- MPAL with recurrent genetic abnormalities
 - MPAL with t(9;22)(q34;q11.2)
 - B/My Leukemia with 11q23 rearrangements
- MPAL without recurrent genetic abnormalities
 - B/My leukemia
 - T/My leukemia
 - Rare types (triphenotypic; B/T)

Lineage Assignment

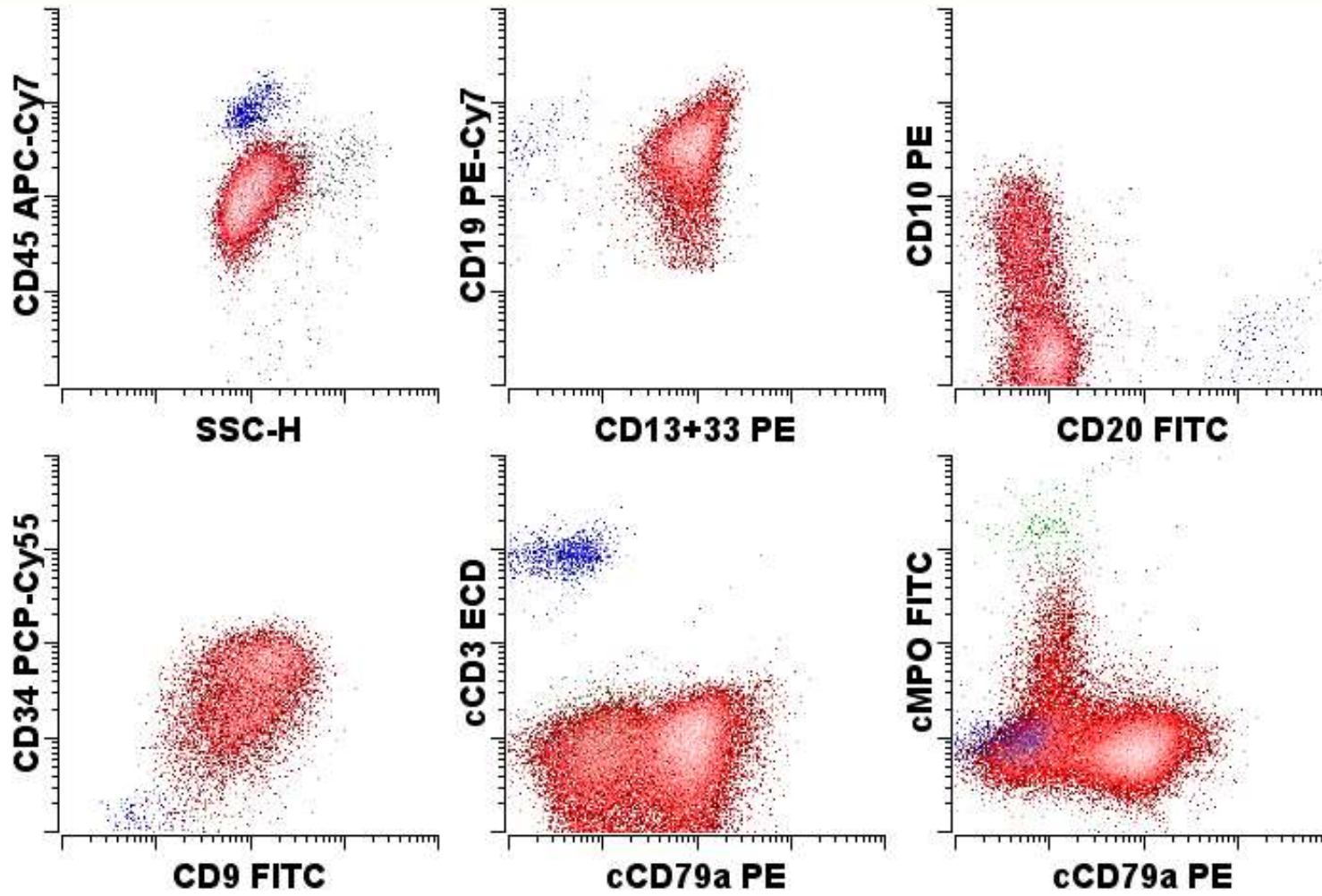
- 1) Two or more distinct populations of cells, one of which would meet criteria for diagnosis of acute leukemia (except that 20% myeloblasts not required)
OR
- 2) Single population of blasts that would meet criteria for T or B-ALL but also expresses MPO or has monocytic differentiation

Myeloid – MPO or monocytic differentiation

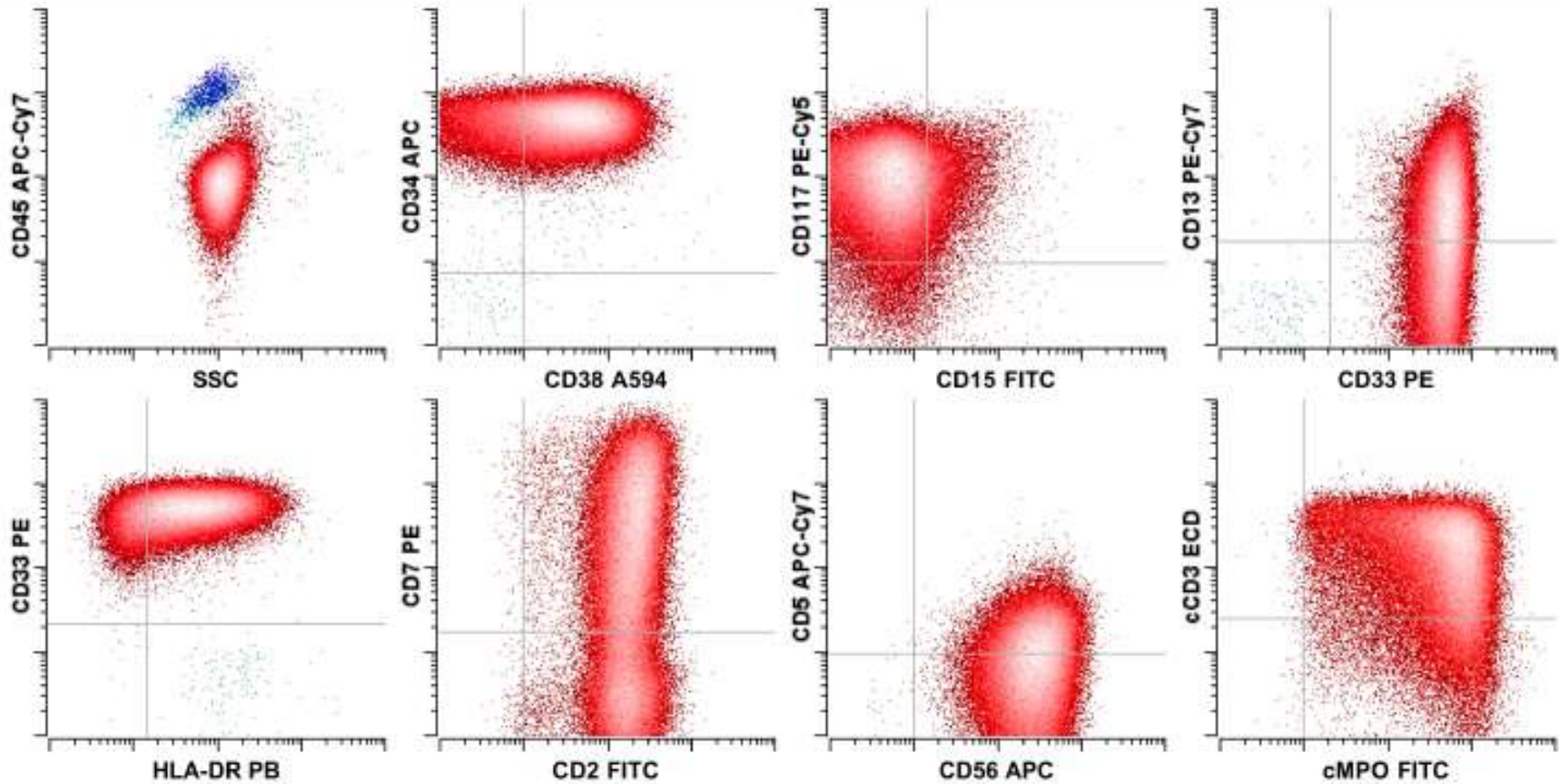
T cell – sCD3 or cCD3

B cell – CD19, CD10 (++), CD79a (++), cCD22 (++)

Bilineal Acute Leukemia



Biphenotypic Acute Leukemia



Myeloid and T cell lineages

Conclusion

- Acute leukemia
 - Immunophenotypic abnormality
 - Blast enumeration
 - Lineage assignment
 - Post-therapeutic monitoring
- Diagnosis requires integration with other techniques